

## Endodontic Enigma – Mandibular Second Premolar with Three Root Canals: A Case Report

Dr. Shalu Krishan<sup>1</sup>, Dr. Navjot Singh Mann<sup>1</sup>, Dr. Amit Bhagat<sup>1</sup>,  
Dr. Tirath Ram Garg<sup>1</sup>

<sup>1</sup>(Conservative Dentistry & Endodontics, National Dental College & Hospital/ BFUHS, India)

**Abstract:** For a high level of success in endodontic treatment it requires a great understanding of root canal anatomy and morphology. The dentists must be prepared to identify those teeth that tend to vary generally from normal anatomy. Thorough shaping, cleaning and obturation of such teeth can be challenging and failing to do so can lead to treatment failure. Mandibular premolars usually have aberrant anatomy. However, the occurrence of three separate canals with three separate foramina in mandibular premolars is very rare. Zilich and Dawson reported 11.7% occurrence of 2 canals and 0.4% of three canals in mandibular second premolar. This case report describes endodontic management of one such tooth with unusual morphological variations in canal anatomy of mandibular second premolar.

**Keywords:** Aberrant anatomy, mandibular premolar, morphologic variation, three root canals

### I. Introduction

Thorough cleaning and shaping of all pulp spaces and its complete obturation are the main objectives of root canal treatment. It is necessary to have proper knowledge of both basic root and root canal morphology and its possible variations for a successful root canal therapy. The presence of an untreated or missed canal may be a reason to failure of endodontic treatment.<sup>1,2</sup> Most of the time clinicians fail to identify the presence of an extra canal particularly in teeth that have anatomical variation. Mandibular premolars are most difficult teeth to treat, probably because of the aberrations in their canal morphology.<sup>3</sup> The incidence of the number of roots and the number of canals reported in anatomical studies varies greatly in the literature.<sup>4,5</sup> It has been observed that 5.3% of mandibular second premolars examined had two canals with two foramen and 44% had two canals with one foramen and only 0.4-5% showed three canal and three foramen configuration.<sup>6</sup> This case report describes diagnosis and treatment recommendations of a rare occurrence of three roots and three canal mandibular second premolar.

### II. Case Report

A 35-year-old patient presented with pain in the lower right side of mandible. The diagnostic radiograph revealed a carious tooth 45 [Fig.1]. The tooth was symptomatic and tender on percussion. The diagnosis was symptomatic irreversible pulpitis with apical periodontitis in relation to the mandibular second premolar. On careful evaluation of the diagnostic radiograph, it was seen that in the mandibular premolar, an extra root was present. Local anesthesia was administered and rubber dam was placed. Access was achieved using a round diamond bur. The two orifices were located one buccal and one lingual. One more orifice located mesiobuccally was also found. Its presence was confirmed with a radiograph. The working length was established radiographically for all the three canals [Fig.2]. Chemo mechanical preparation was performed using the ProTaper File system (Dentsply-Maillefer, Ballaigues, Switzerland) in a crown-down manner. A 5.25% solution of sodium hypochlorite and 17% EDTA was used alternatively as irrigants at every change of instrument. The apical preparation was done till the F2 file size in all the 3 canals and the canals were obturated with corresponding ProTaper F2cones. A postobturation radiograph was recorded [Fig.3].

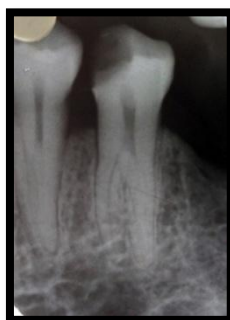

Fig 1- Preoperative radiograph

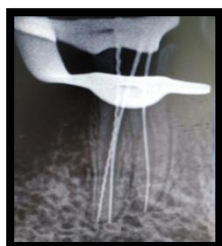


Fig 2- Working length radiograph

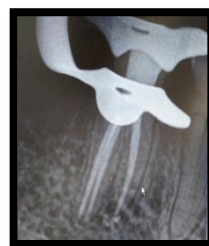

Fig 3- Obturation and Post obturation

### III. Discussion

Morphology of the root and the canals of mandibular second premolar is usually complex and variable. Mandibular second premolars with two root canals have been reported on several occasions. But the occurrence of three separate canals is very rare. An incidence of 0.4% of mandibular second premolar with three root canals is reported.<sup>5</sup> Two separate and distinct root canals were reported in 2.5% of mandibular second premolars by Vertucci, but he has not reported any case of mandibular second premolar with three root canals.<sup>7</sup> Various published studies<sup>7-11</sup> citing the anatomy and morphology of mandibular premolars report that approximately 98% of the teeth in these studies were single rooted. The incidence of two roots was 1.8%. Three roots when reported were found in 0.2% of the teeth studied. Four roots were rare and were found in less than 0.1% of the teeth studied. Usually the complex nature of the root and root canal morphology of the mandibular second premolar has been underestimated. The following points from diagnostic information and techniques might help in detecting additional root(s) and canal(s). A second radiograph at an angle of 15-20 degrees from either mesial or distal from the horizontal long axis of the root is necessary to accurately diagnose the number of roots and canals in premolar teeth. On a parallel radiograph sudden narrowing of the canal system suggests canal system multiplicity.<sup>12</sup> Martinez-Lozano *et al.* have suggested a 40-degree mesial angulation of the x-ray beam to identify additional canals.<sup>13</sup> Teeth with extra roots and/or canals pose a particular challenge. To locate these extra canals, it requires proper instruments and the knowledge to use these instruments effectively. Failure to identify and treat these additional root canals may cause treatment failures. Careful examination of preoperative radiographs can aid in locating additional canal or roots. By using x-rays from different angulations, efficient explorers, wider access openings, adequate illumination and, whenever possible, image magnification might help in detection of extra canals. Proper precautions should be taken during root canal therapy of these teeth and hence instrumentation of these canals was carried out using nickel titanium files, due to their flexibility, lesser risks of ledge formation and perforations.

### IV. Conclusion

The incidence of more than one root, more than one canal, and more than one foramen is less frequent in mandibular second premolar than first premolar. When performing root canal therapy, additional canals might be missed, leading to a greater failure rate. This case has been reported to share our experience and increase the awareness of clinicians on aberrations in tooth morphology of mandibular premolar teeth for a more predictable treatment outcome.

### References

- [1] Vertucci FJ. Root canal morphology and its relationship to endodontic procedures. *Endod Topics*, 2005, 10, 03-29
- [2] Aguiar C, Mendes D, Camara A, Figueiredo J. Endodontic treatment of a mandibular second premolar with three root canals. *J Contemp Dent Tract*, 2010, 11, 78-84.
- [3] Slowey RR. Root canal anatomy: Road map to successful endodontics. *Dent Clin North Am*, 1979, 23, 555-73.
- [4] Trope M, Eلفenbein L, Tronstad L. Mandibular premolars with more than one root canal in different race groups. *J Endod*, 1986, 12, 343-5.
- [5] Zillich R, Dowson J. Root canal morphology of mandibular first and second premolars. *Oral Surg Oral Med Oral Pathol Oral Radiol*, 1973, 36, 738-44.
- [6] Lin Z, Ling J, Jhugroo A. Mandibular first and second premolars with three canals. *Internet J Dent Sci*, 2006, 4:1.
- [7] Vertucci FJ. Root canal anatomy of human permanent teeth. *Oral Surg Oral Med Oral Pathol*, 1984, 58, 589-99.
- [8] Cleghorn BM, Christie WH, Dong CC. The root and root canal morphology of the human mandibular first premolar: A literature review. *J Endod*, 2007, 33, 509-16.
- [9] Calikan M, Pehlivan Y, Septeciolu F, Turkun M, Tuncer SS. Root canal morphology of human permanent teeth in a Turkish population. *J Endod*, 1995, 21, 200-4.
- [10] Sert S, Aslanalp V, Tanalp J. Investigation of the root canal configurations of mandibular permanent teeth in the Turkish population. *Int Endod J*, 2004, 37, 494-9.
- [11] Iyer VH, Indira R, Ramachandran S, Srinivasan MR. Anatomical variations of mandibular premolars in Chennai population. *Indian J Dent Res*, 2006, 17, 7-10.
- [12] Yoshioka T, Villegas JC, Kobayashi C, Suda H. Radiographic evaluation of root canal multiplicity in mandibular first premolars. *J Endod*, 2004, 30, 73-4.
- [13] Martinez-lozano MA, Forner-Navarro L, Sanchez-Cortes JL. Analysis of radiologic factors in determining premolar root canal systems. *Oral Surg Oral Med Oral Pathol Oral Radiol Endod*, 1999, 88, 719-22.